

Activating mutation M453V in receptor TSHR as a cause familial hyperthyroidism



Beata Sawicka¹, Alexandra Stephenson², Hanna Borysewicz-Sańczyk¹, Justyna Michalak¹, Karolina Stożek¹, Tanja Diana³, George Kahaly³, Ralf Paschke², Artur Bossowski¹

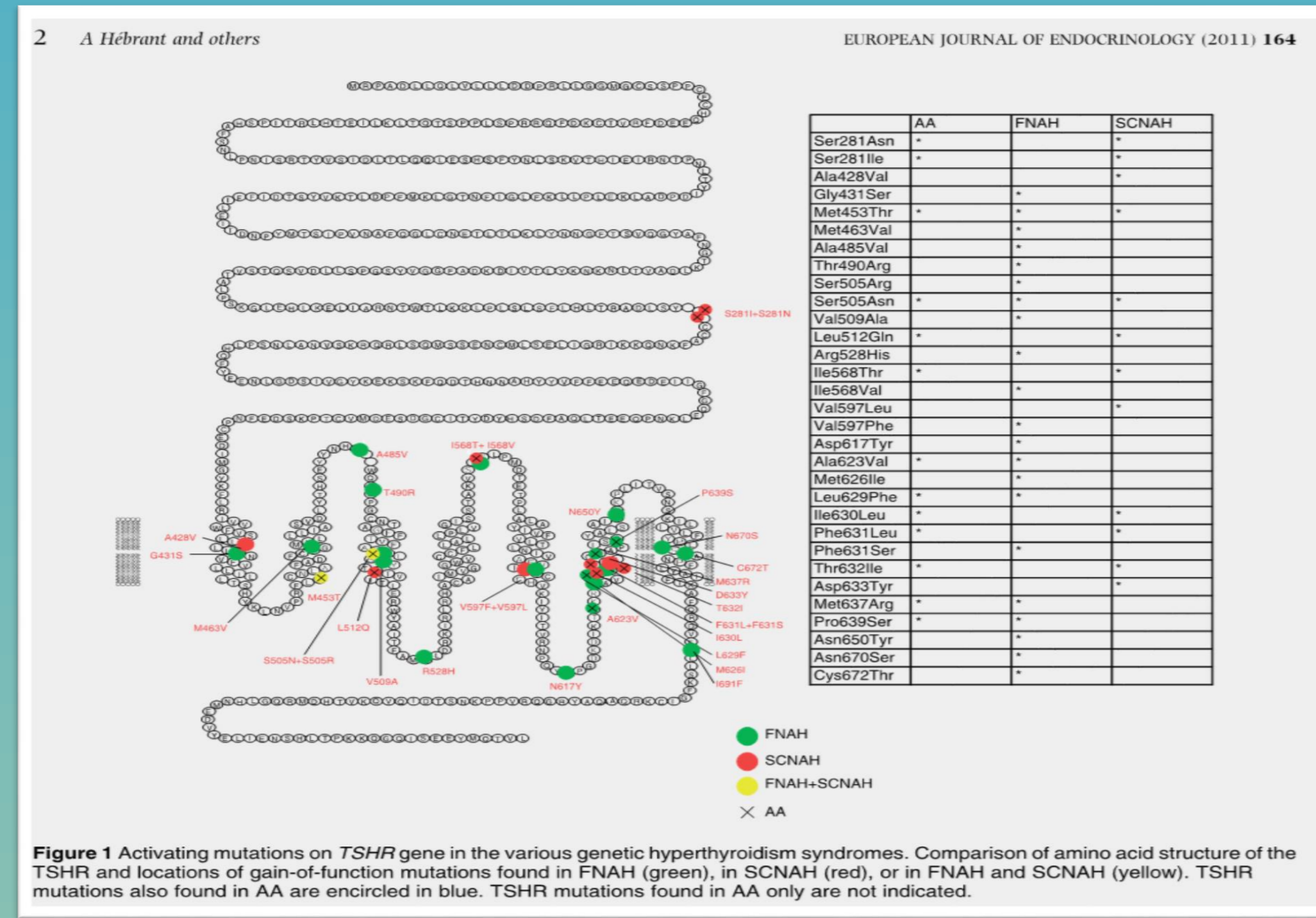
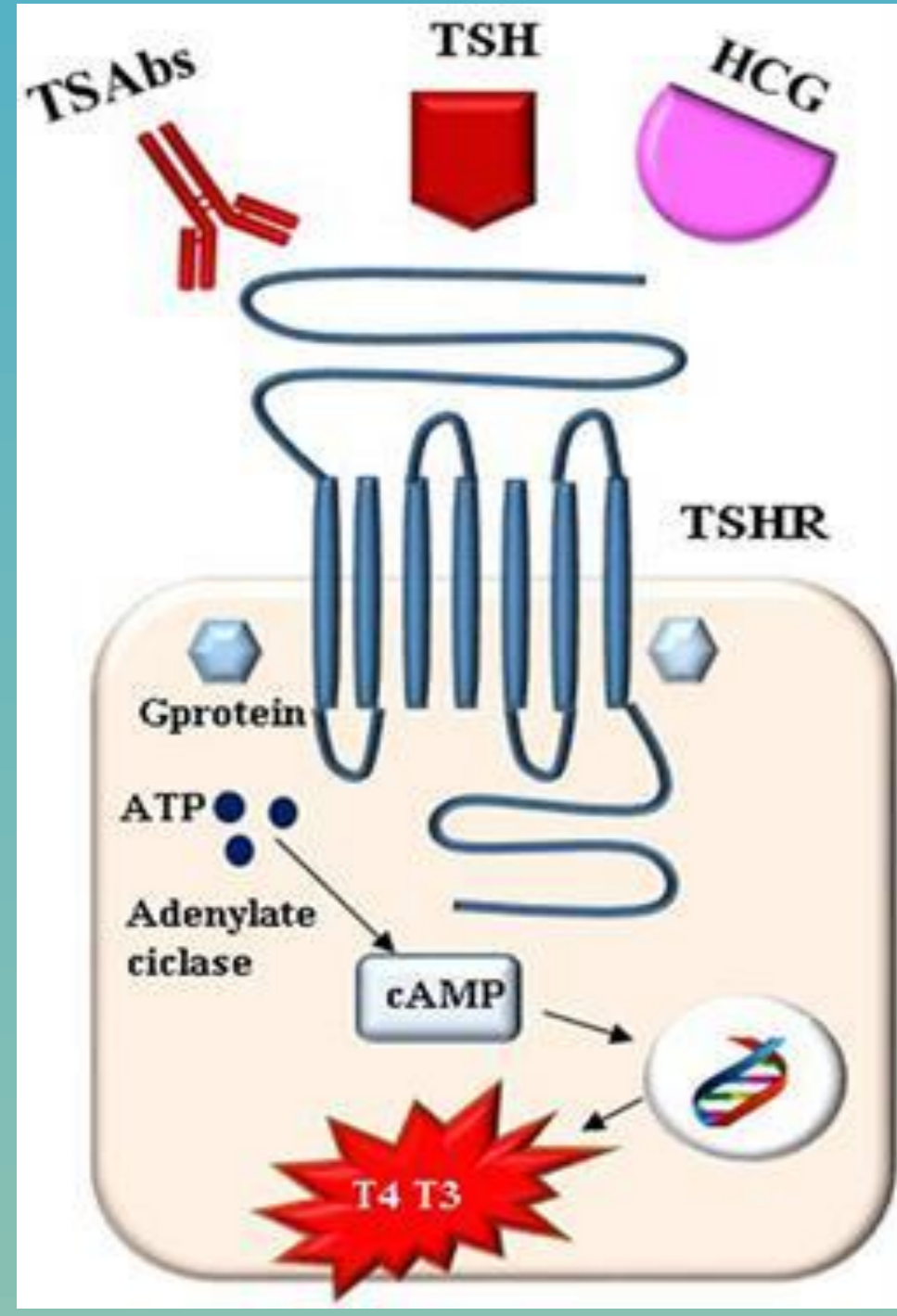
¹Department of Pediatrics, Endocrinology, Diabetology, with Cardiology Division. Medical University in Białystok, Poland

²Division of Endocrinology and Metabolism Zone, Departments of Medicine, Oncology, Pathology & Laboratory Medicine, and Biochemistry and Molecular Biology. University of Calgary, Kanada

³ Molecular Thyroid Research Laboratory. Johannes Gutenberg University, Mainz, Germany

Background

The most common hyperthyroidism in children is connected with excessive levels of thyroid hormones as an effect of activation thyrotropin receptor (TSHR) by uncontrolled production anti-thyroid-stimulating antibodies in Graves' disease. The other rare cause of hyperthyroidism is activating mutation in receptor TSHR in thyroid gland.



TSHR	Exon
C.100G>A p.(Glu34Lys) (rs45499704)	1
c.106G>C p.(Asp36His) (rs61747482)	1
c154C>A p.(Pro52Thr) (rs2234919)	1
c.10001T>C p.(Ile334Thr) (rs553893026)	10

Ines Ines; Cesidio Giuliani; Giorgio Naplitano; Thyroid-stimulating Hormone Receptor Antibodies In Pregnancy: Clinical Relevance; Front. Endocrinol., 2017

Hebrant A., van Staveren W.C.G, Maenhaut C., Dumont J.E., Leclere J; Genetic hyperthyroidism: hyperthyroidism due to activating TSHR mutations; European Journal of Endocrinology (2011) 164; 1-4

Wariants of activating mutation M453V in receptor TSHR (chromosome 14q31)

Cases reports

CASE NO 1- 11-year-old boy

- He was born from first pregnancy at term by Caesarean section. During gestation his mother was treated with thyreostatic drugs because of hyperthyroidism. Thyroid hormones and antithyroid antibodies were checked because of bradycardia in newborn and his thyroid disorders' family history. Then we diagnosed hypothyroidism and started therapy with L-thyroxine (10ug/kg/day orally). Because of rapid normalisation of TSH, low levels of his antithyroid antibodies and normal thyroid gland by ultrasonography we decreased the dose of l-thyroxin and finished his therapy with l-thyroxin when he was 6 months. His motor and mental development was normal.
- When he was 3 years, he lost his body mass, he had tachycardia and advanced bone age (7 years). In laboratory labs TSH was decreased (0 uIU/ml); elevated free thyroid hormones (fT3- 8,09 pg/ml (↑); fT4- 2,61 ng/ml (↑), with normal level of anti-thyroid antibodies (TPO- 5 IU/ml; ATG< 10 IU/ml, anti-TSH- 0,77; TSI-52; TBI-19%). In ultrasonography thyroid tissue was with excessive flow. We diagnosed hyperthyroidism and we started treatment with taking methamizole in 3 doses (1 mg per kg daily orally), beta- blocker in dose 1 mg per kg once a day orally and vit.B (1 tbl. daily orally). We had not observed any side effects connected with the anti-thyroid therapy. We modified the doses of thyreostatic drugs according to levels of thyroid hormones. The tests of stopped that therapy were ineffective and now we make a plan the radical therapy.

CASE NO 2- his 40-year-old mother

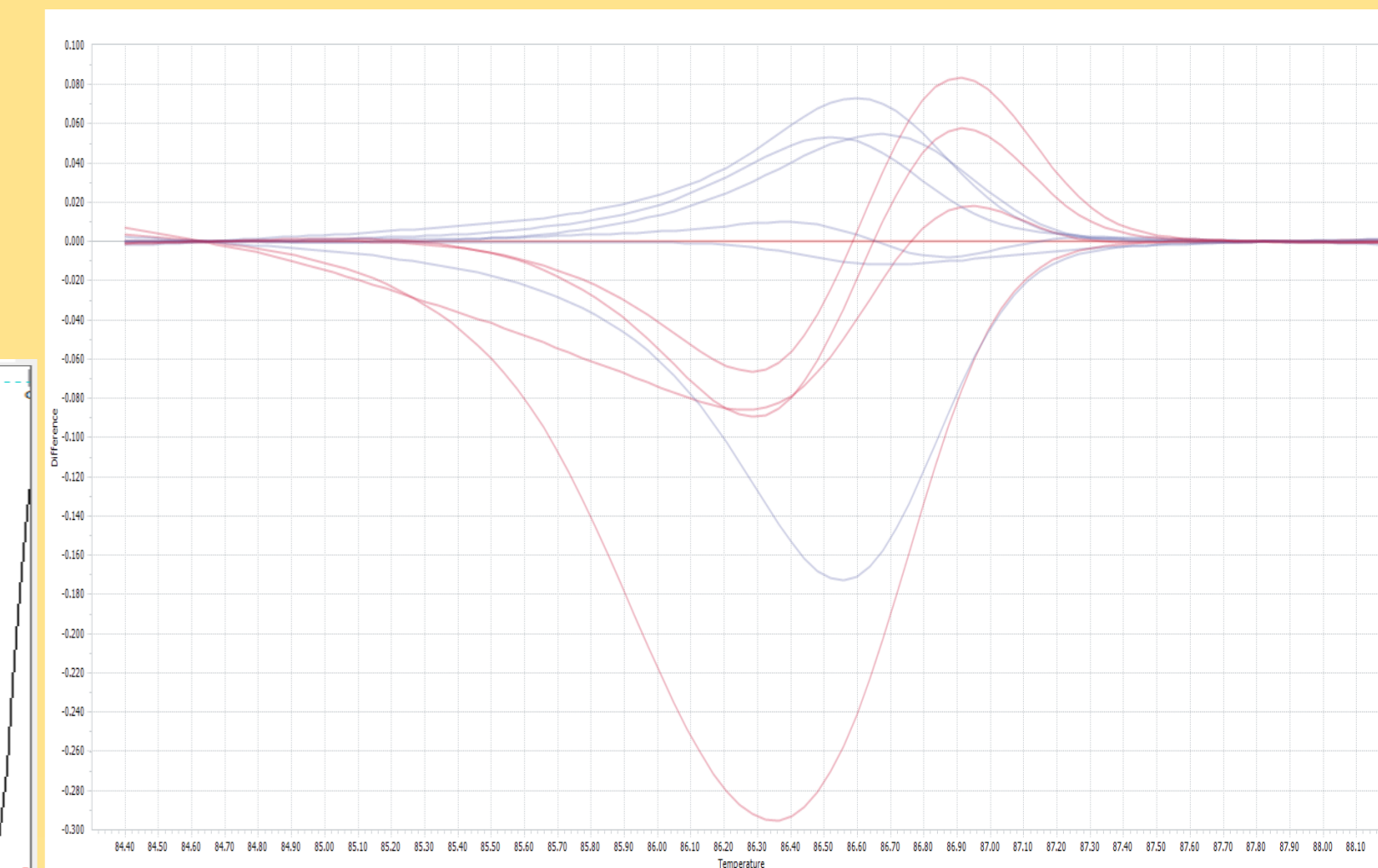
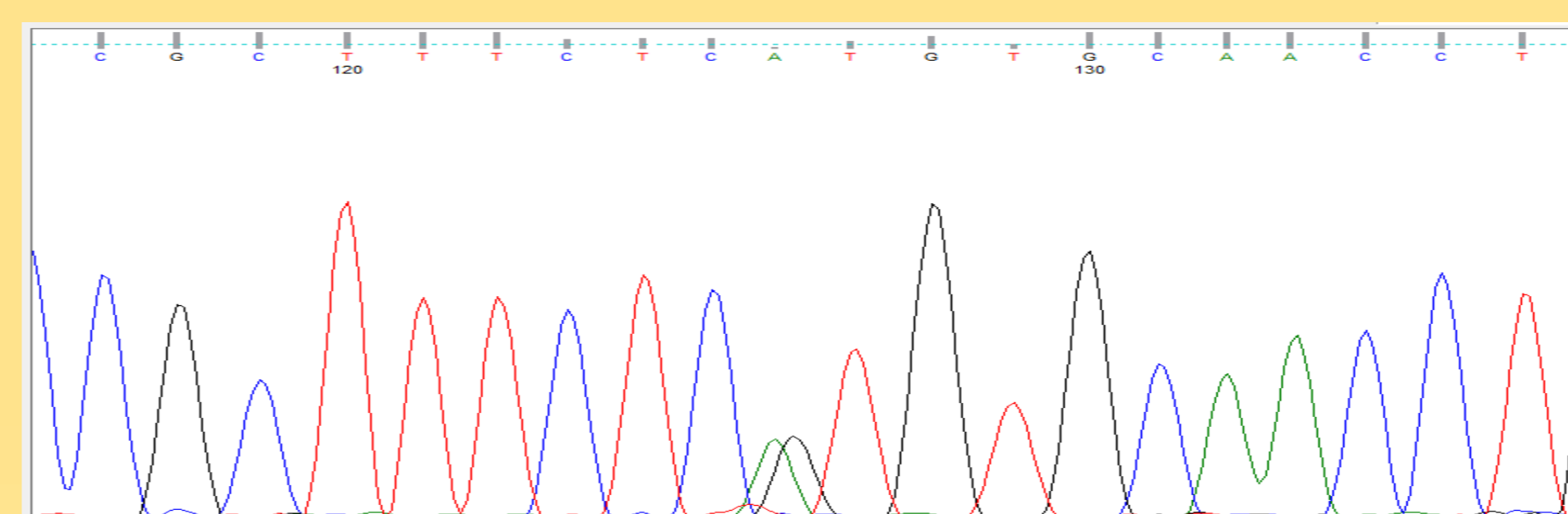
- She was diagnosed hyperthyroidism when she was 6 years. She started the typical therapy of hyperthyroidism (thyreostatic drugs and beta- blockers in appropriate doses). She had positive family history with Graves' disease (her father and her 2 siblings).
- Because of ineffective drug therapy, she had *strumectomy* at 12-yrs aged. Because of recurrence of hyperthyroidism and presenting enlarged multinodular goitre pressing trachea in ultrasonography, she had the *second strumectomy*, when she was 30 years old. After surgery she had *radioiodine therapy* to eliminate thyroid tissue. In effect now she has hypothyroidism and she is administered with l-thyroxin.

CASE NO 3 – 8- year- old- boy

- He was born from first pregnancy at term by Caesarean section (was born after second strumectomy and after radioiodine therapy), was admitted to our Outpatient Clinic when he was 6 years because of hyperthyroidism [fT3- 8,24 pg/ml (↑); fT4- 2,76 ng/ml (↑); TPO- 13,6 IU/ml (N); ATG< 10 IU/ml (N); anti-TSH- 0,72 (N) and we started appropriate therapy (MMI 0,5mg/kg/dz.; β-blocker 0,5mg/kg/d.).

Results

In order to find genetic basic of familial hyperthyroidism we sent blood samples obtained from the two children and both parents to Division of Endocrinology and Metabolism Zone, Departments of Medicine, Oncology, Pathology, and Biochemistry and Molecular Biology Arnie Charbonneau Cancer Institute Cumming School of Medicine in University of Calgary in Canada. In mother and her children was identified **a novel activating mutation M453V in receptor TSHR (heterozygous c.1357A>G)**, which initiates excessive production thyroid hormones and hyperthyroidism.



Conclusions

- 1/. In case of familial hyperthyroidism it is worth to find and identify mutation in genes in receptor TSHR, which may determinate risk assessment of hyperthyroidism and may use earlier appropriate therapy.
- 2/. The patients with activating mutation in receptor TSHR often need radical therapy, because long term therapy with thyreostatic drugs is ineffective.

