

## INTRODUCTION

**Atypical hemolytic uremic syndrome (aHUS)** is a rare, life-threatening disease due to complement dysregulation that damage endothelial cells and consequently causes intravascular formation of microthrombi in renal arterioles and capillaries. Although the renal microvasculature appears to be the predominant target, other organs can be affected.

**Eculizumab, a humanized antibody against complement protein C5, inhibits activation of the terminal complement pathway, making the continuous endothelial damage and microthrombi formation stop.**

In this report, we discuss the case of a **patient with relapsing aHUS with rare cutaneous involvement and her treatment with eculizumab.**

A 35-year-old female presented in our hospital with relapsing painful skin lesions. Her past medical history is: CKD in haemodialysis due to aHUS, diagnosed after her second pregnancy two years ago. Two months after the childbirth, she was presented with severe hypertension and edema and the study performed showed microangiopathic hemolytic anemia, thrombocytopenia and acute kidney injury possibly triggered by pregnancy or respiratory infection. She started on plasma exchange (PE) with the normalization of the hemolysis parameters but with permanent kidney failure and remained dialysis dependent. Genetic tests were performed and sequencing analysis of all the exons of the CFH and MCP gene identified an homozygosis CFH mutation: 332C>T, V62I, Y402H, Q672Q e E936D - TGTGT, on 21 exon and an heterozygosis MCP mutation: intron 2, c.287- 2A>G, IVS2-2A>G. During the first year after diagnosis, two aHUS recurrences occurred. The first one presented isolated hematological commitment (hemolytic anemia and thrombocytopenia) that was resolved after 6-month PE. Four months after PE withdrawal, she started to complain of painful leg skin lesions that progressed to ulcers, with some necrotic areas of the base and edges (Figure A). Skin biopsy showed fibrin thrombi in the small blood vessels, with discrete inflammatory infiltrate of lymphocytes and plasma cells (Figure B). One month after the lesion's appearance the patient developed an uncontrolled hypertension and relapse of the hematological commitment. PE led to the resolution of hematological and cutaneous disorders (Figure C) and was maintained for another 6 months. Five months after PE stop the patient had another cutaneous relapse.

This acute exacerbation was partially responsive to PE, with persistent signs of anemia and thrombocytopenia and partial improvement of skin lesions. **Eculizumab was initiated and PE was stopped and no additional PE treatment was done since the initiation of eculizumab. After starting eculizumab, the cutaneous ulcer was completely healed, platelet count increased, haptoglobin level normalized and there was a reduction of the need of erythropoietin dose and anti-hypertensive drugs. The patient has been receiving eculizumab for the past 11 months without signs of recurrence of hematological or dermatological lesions.**

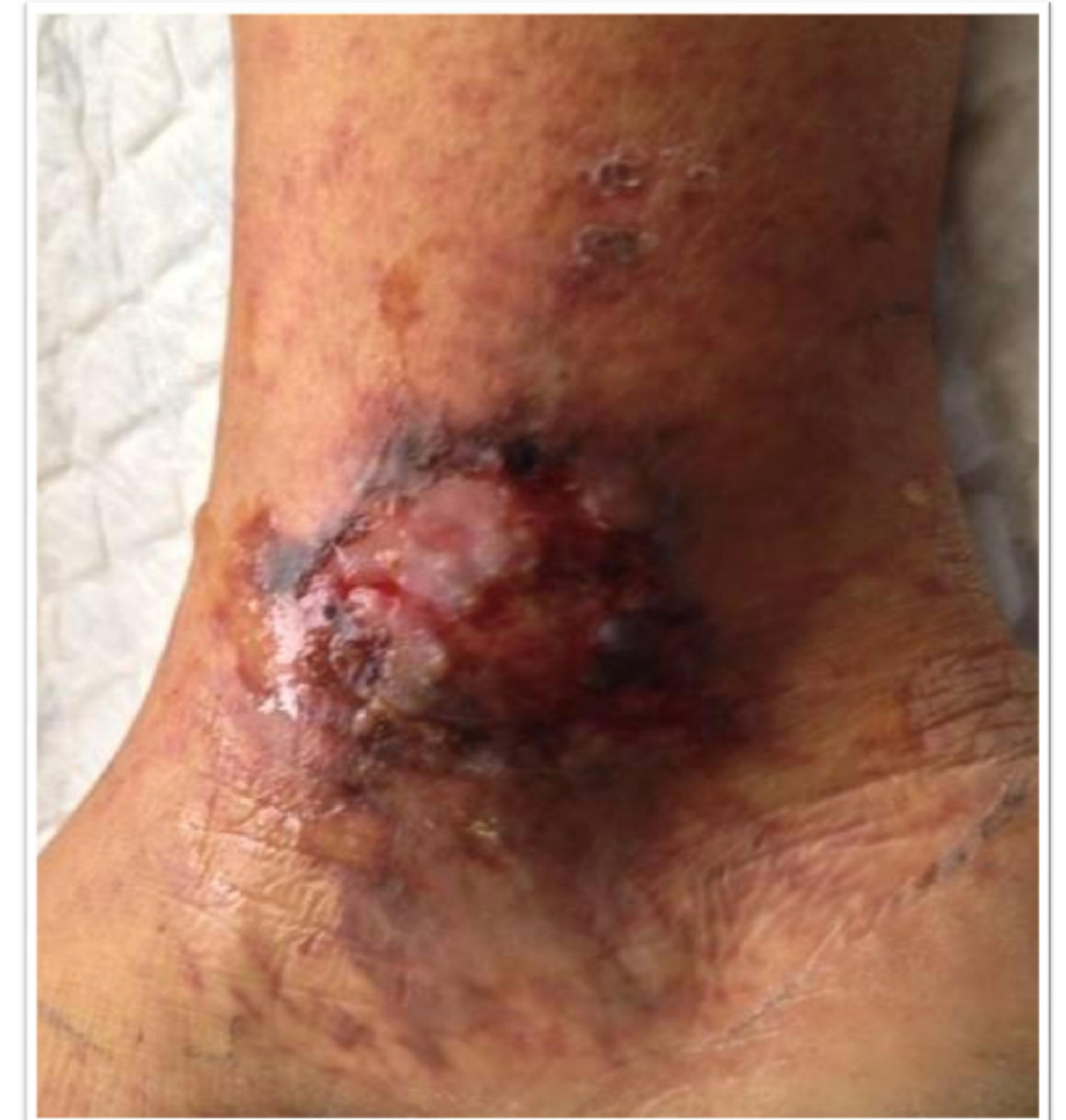

Figure A

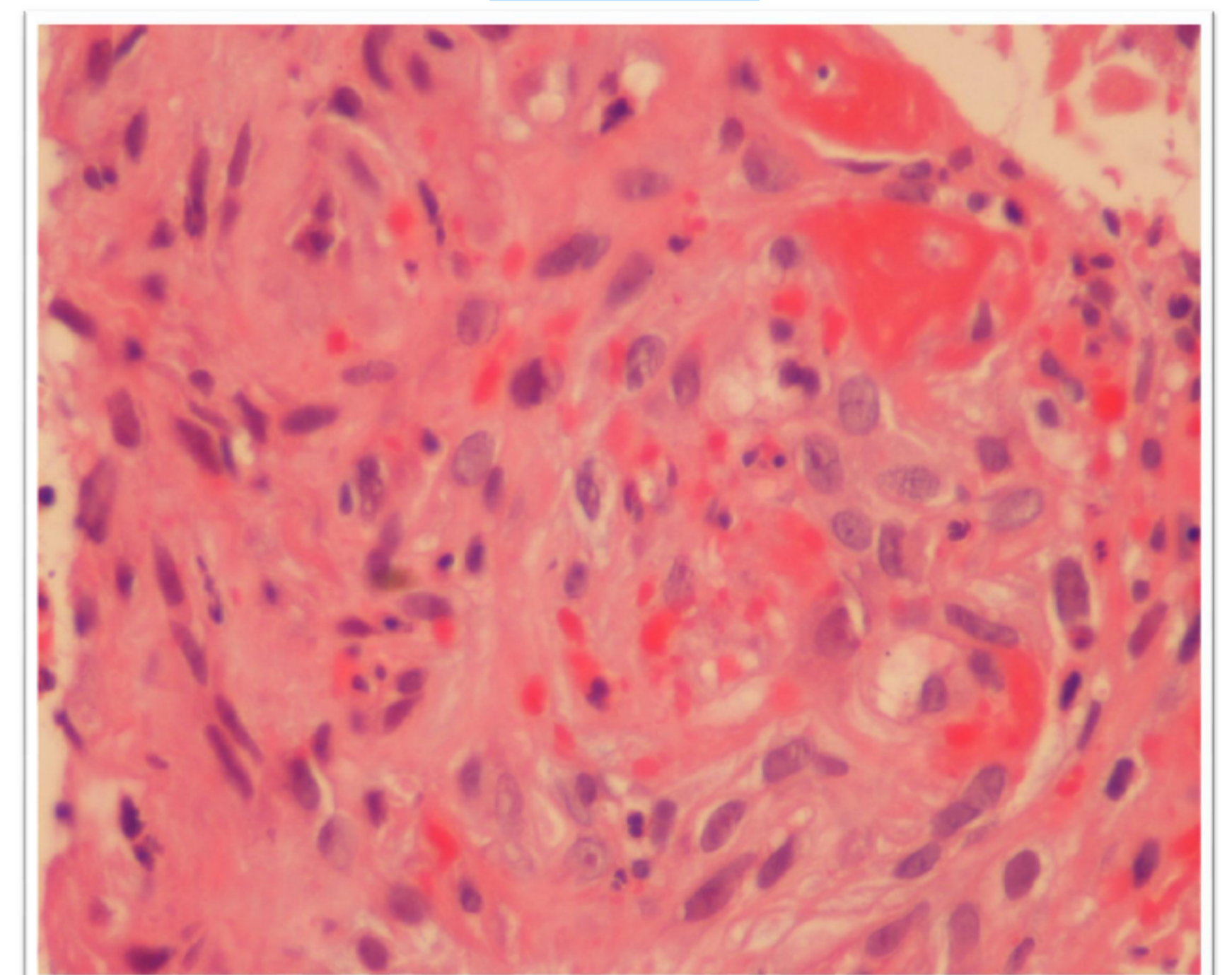


Figure B

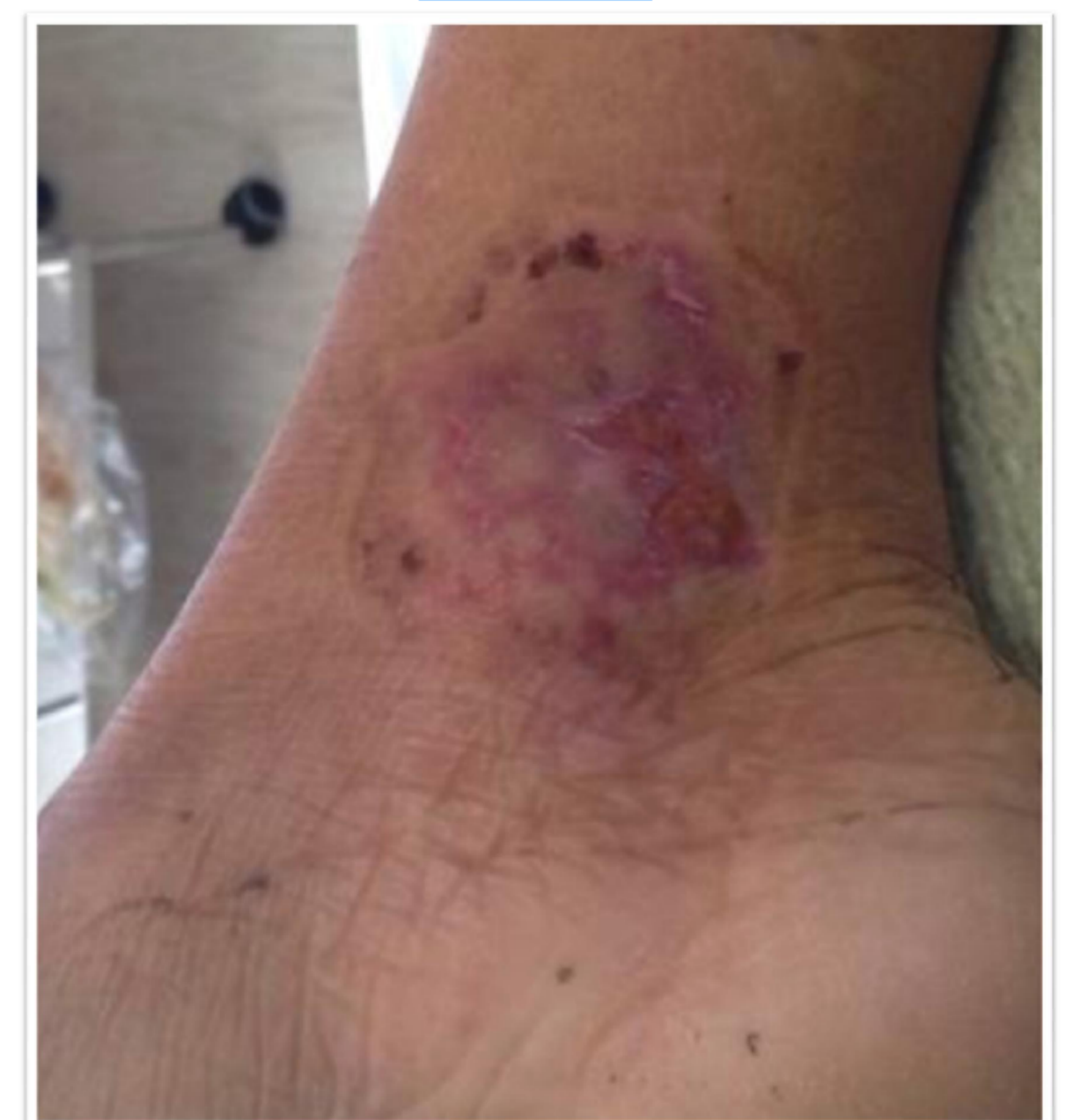

Figure C

## CONCLUSIONS

**Eculizumab** inhibited the thrombotic microangiopathy and efficiently stopped hemolysis, **promoting the healing of the skins lesions without other treatment and without recurrence.**

**Eleven months of eculizumab treatment in a patient with aHUS previously PE dependent were proved to be safe.**

## REFERENCES

- Legendre CM, et al. Terminal complement inhibitor eculizumab in atypical hemolytic-uremic syndrome. N Engl J Med 2013; 368: 2169-81.
- Zuber J, et al. Use of eculizumab for atypical haemolytic uraemic syndrome and C3 glomerulopathies. Nat Re Nephrol 2012; 8:643-57
- Loirat C, et al. Atypical hemolytic uremic syndrome. Orphanet J Rare Dis 2011, 6 (1):60.
- Noris M, et al. Atypical Hemolytic-Uremic Syndrome. N Engl J Med 2009; 361:1676-87.

