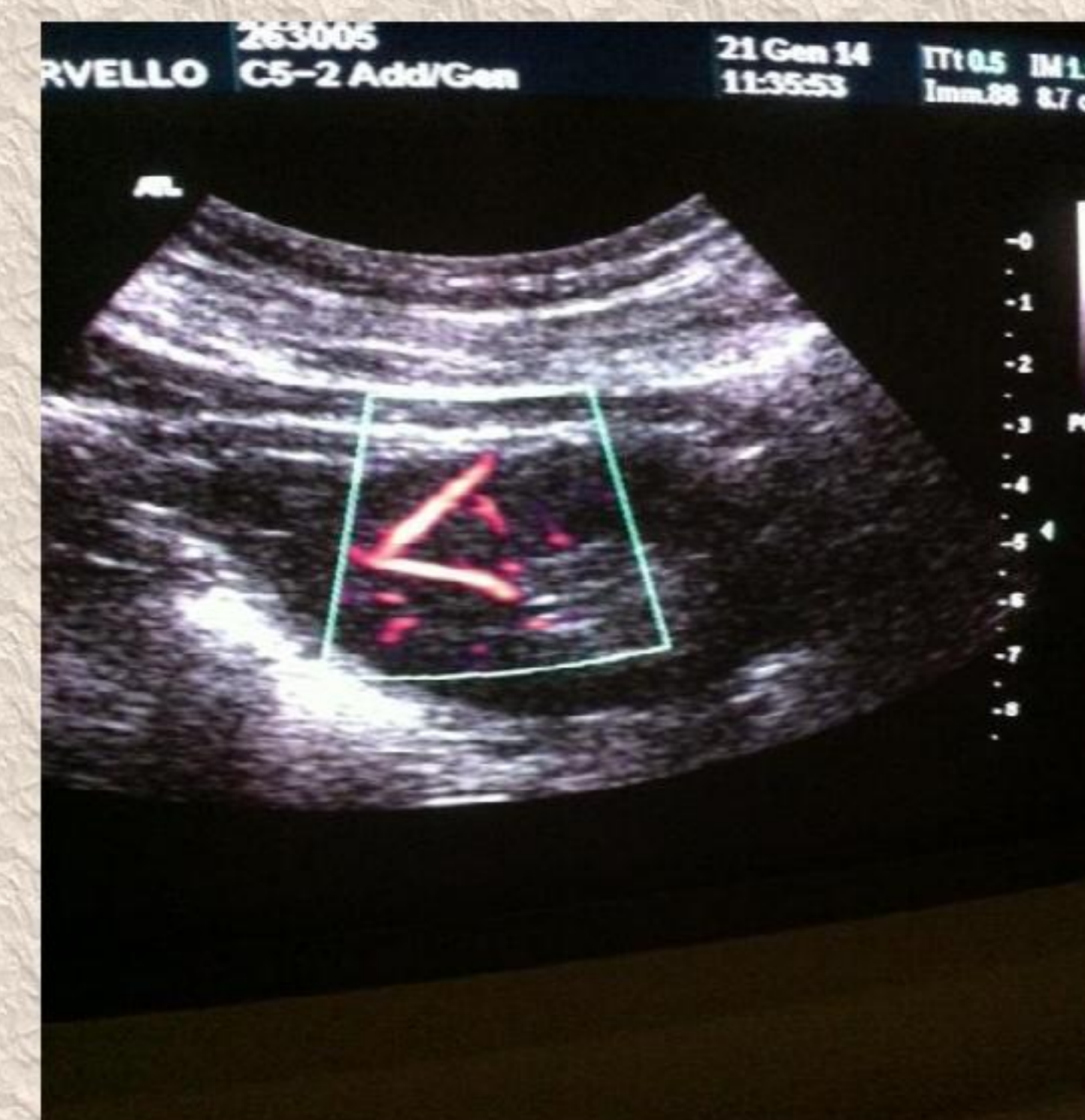

# KIDNEY DISEASES AND RENAL BIOPSY A TEN YEAR EXPERIENCE

Domenico Ferrara\*, M.L. Amico\*, M.C. Lorito\*, L. Visconti\*, F. Valenza°, F. D'Amato°, GiuseppeVisconti\*

\*Nephrology and °Radiology, Hospital Villa Sofia-Cervello, Palermo, ITALY



## INTRODUCTION and OBJECTIVES

Between 2001 and 2012 we collected 300 native kidney biopsies, for the diagnosis of the following clinical syndromes: acute or chronic renal failure with not clear etiology, nephrotic syndrome, proteinuria > 1g/day.

Kidney biopsies were taken with the automated biopsy gun (15G needle) under real-time ultrasound and were examined by light microscopy and immunofluorescence.

## METHODS

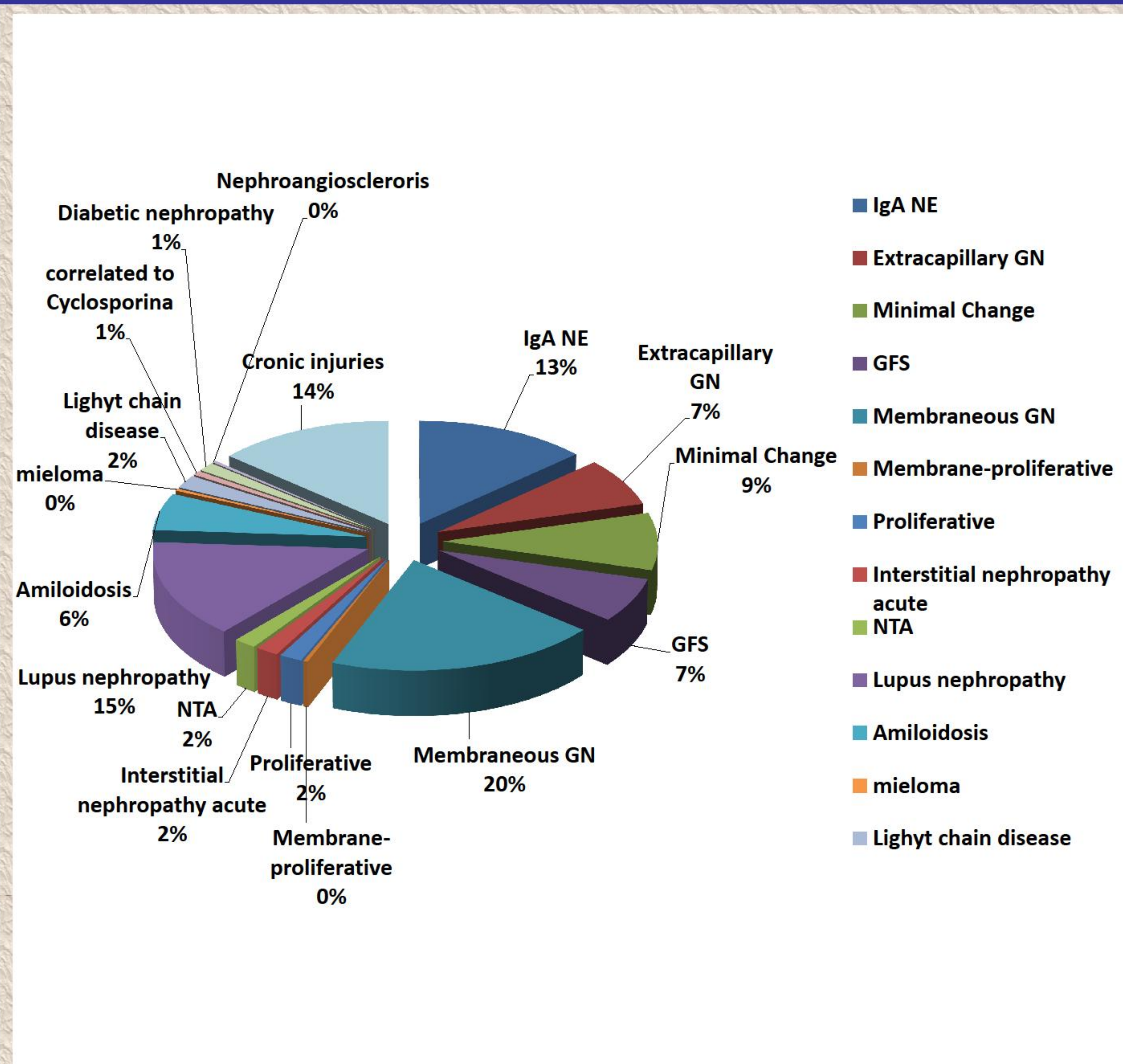
### The most common diagnoses were primitive:

- ❖ membranous nephritis,
- ❖ lupus nephropathy,
- ❖ IgA nephropathy,
- ❖ extracapillary glomerulonephritis
- ❖ kidney amyloidosis.

### The clinical diagnoses were: 40 nephropathy IgA,

- ✓ 22 GN extracapillary,
- ✓ 26 Minimal change,
- ✓ 20 GFS,
- ✓ 60 GN membranous,
- ✓ 1 GN membranoproliferative,
- ✓ 5 GN proliferative,
- ✓ 6 acute interstitial nephropathy,
- ✓ 5 acute tubular necrosis,
- ✓ 44 lupus nephritis,
- ✓ 17 cases of amyloidosis,
- ✓ 1 myeloma,
- ✓ 6 light chain disease,
- ✓ 2 secondary to cyclosporine,
- ✓ 4 diabetic nephropathy,
- ✓ 1 nephroangiosclerosis,
- ✓ 40 cases with prevalent chronic injuries.

The biopsies with chronic renal lesions were numerous, 13,4% overall, with an annual rate unchanged.



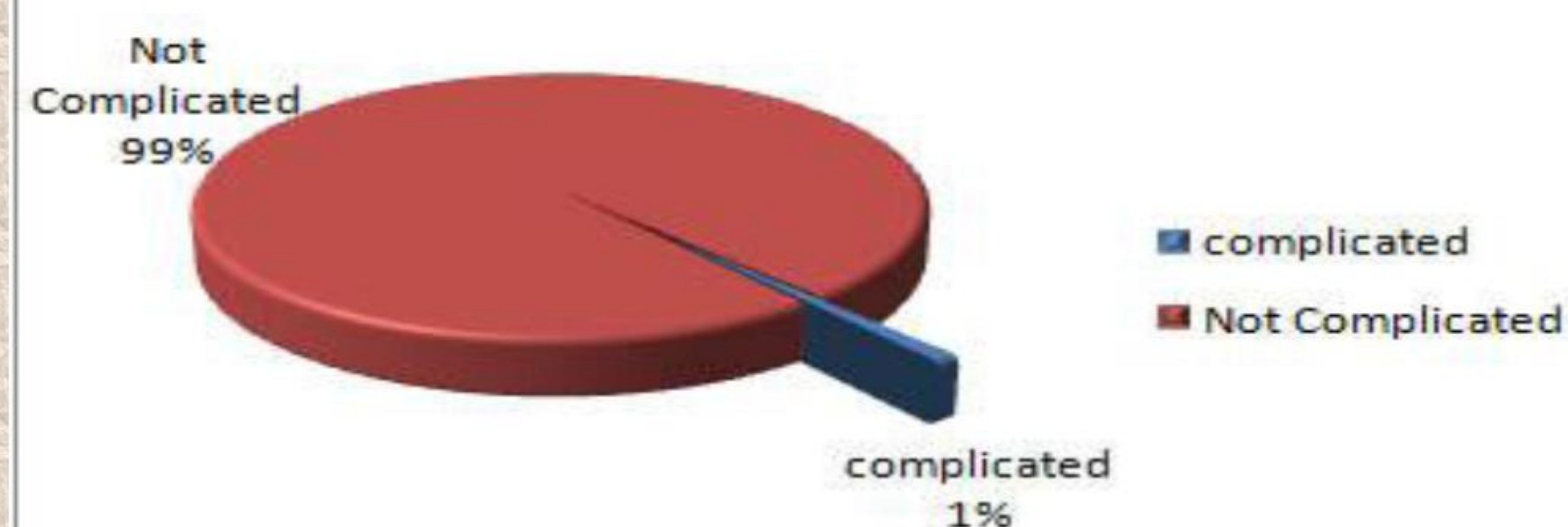
## RESULTS

### Complications

In our center between 2001 and 2012 the only complications were the hemorrhagic ones.

The patients with macroscopic hematuria were 3 out of 300 cases (1%), and this complication was resolved with observation and bed rest for the following 24-36 hours.

### Percentual distribution: cases with and without complications



## CONCLUSIONS

In ten years we examined a population with increased both numeric and multiethnic, however the annual percentage of each diagnosis was unchanged.

The annual elevated rate of patients with chronic renal lesions is a sign of late diagnosis of the kidney diseases.

