




IPFW Blaubeuren - München



Ultrasonography of joints and correlation with function in Haemophilic Arthropathy in children and young adults - interim results of a clinical pilot trial (HämarthroSonoPilot)

Sigl-Kraetzig, Michael^{1,2}, Seuser, Axel³, Wendel, Mareike³

¹ IPFW - Institute for Pediatric Research and Further Education Blaubeuren / Munich, Germany, ² Pediatrician Practice and Haemophilia Treatment Center, Blaubeuren, Germany, ³ Institute for Motion Analysis (IBQ), Bonn, Germany
corresponding author: IPFW - Dr. Sigl-Kraetzig, Weilerstr. 41, D-89143 Blaubeuren, ipfw@forschung-weiterbildung.de

Purpose:

Sonography is well-used in routine clinical practice to examine joint bleedings in patients with severe bleeding disorders like Haemophilia A, Haemophilia B or severe forms of the von Willebrand's disease (especially type 3). In Germany, about 4,000-5,000 patients living with severe or moderately severe haemophilia.

Joint damage from bleeding complications affect 90% of the patients with severe haemophilia and represent the vast majority of the complications of this disease. Ankle joints, knees and elbows are most commonly affected and good accessible by ultrasound examination. The haemophilic arthropathy (HA) is caused by recurrent haemorrhages in the joints. Even by prophylactic treatment with coagulation factor concentrates not every synovial haemorrhage can be prevented: Despite prophylaxis subclinical bleedings can occur, recurrent events lead to synovitis, following an increasing synovial hypertrophy with long-term failure load of joint-forming structures, particularly the knees and the ankles.

The 3D-motion-analysis helps to understand these processes by providing information about the forces and stresses acting on the joints during movement. But the 3D motion analysis does not provide information on the structural changes of hemophilic joints.

Conventional radiography is used to represent osseous destruction with progressive changes of hemophilic arthropathy. However, frequent follow-up of joint changes are hereby not recommended because of the radiation exposure. In addition, conventional radiography can not adequately present synovitis, small bruises or minor cartilage defects. The sensitivity to inflammation of the synovium, especially in the early stages of the disease, is very limited. In contrast, Magnetic resonance imaging (MRI) provides detailed information on all aspects of haemophilic joint changes such as effusion, synovial hypertrophy, bleeding and early osteochondral abnormalities, but it's expensive and not readily available.

Diagnostic Ultrasound is more sensitive than radiography in the detection of joint effusion and synovial changes. Compared with MRI, sonography provides a shorter examination time, lower costs and requires even in young patients, no sedation or anesthesia. However, the ultrasound has restrictions such as higher examiner dependence and only partially representability of many joints as osseous structures can't be penetrated by the diagnostic ultrasound.

Up to now some protocols for examination of the joints of haemophilic patients with ultrasound were published to show signs of HA with effusion, synovitis, cartilage defects or subchondral bone damage. None of the so far published protocols was standardized and feasible enough to be used by the haemophilia treaters themselves during routine examination in outpatient departments. In 2013 the first easy-to-learn standardized protocol and scoring system (HEAD-US) for scanning HA-joints with ultrasound was published by C. Martinoli. For the presentation of synovitis or effusions as a sign of progression of HA standardized sonographic section planes are therefore now available.

Up to now no correlation of function and imaging of joints with HA was investigated. In this study sonographic findings in HA are correlated with data from an ultrasonic motion-analysis of the knees and the results of an orthopedic examination for the first time worldwide.

Results

In patients with significant disease activity in the HEAD-US ultrasound score (activity >= 1) and clinical remarkable capsule pain and/or swelling (highlighted in Table below) also strikingly pathological sliding in motion analysis can be detected except one patient. In 7 of 20 patients with an abnormal sonographic score for the activity of haemophilic arthropathy (activity >= 1), no clear clinical joint pathology shows in the orthopedic examination, but in 4 patients without clinical signs in the examination a bad rolling-sliding ratio in the motion analysis attracts attention.

Index	HEAD-US activity		ligament pain	capsule pain	swelling	walk total	knee-bands total	rolling-to-slide	motion total	age (years)	Haemophilia vWFS	activity / type
	ultrasound	clinical exam.										
KA	0	0	-	-	-	0	0	30	30	3	A	<1%
DJ	0	0	-	-	-	25	77,5	30	132,5	6	A	<1%
PL	0	0	-	-	-	99	65	60	254	22	VWS 2A	
FA	0	0	-	-	-	99	90	30	219	28	A	<1%
ZJ	0	0	-	-	-	59	85	45	189	7	A	<1%
LA	0	0	-	-	-	65	65	30	160	7	A	<1%
MM	0	0	-	-	-	82	87,5	30	199,5	11	A	>5%
KS	1	0	-	-	-	32	87,5	30	149,5	6	VWS 3	
RH	1	0	-	-	-	81,5	105	30	216,5	23	A	1-5%
HJ	1	0	-	-	-	no motion analysis				3	A	<1%
FM	1	0	-	-	-	113	85	60	258	25	A	<1%
WP	1	0	-	-	-	113,5	100	60	273,5	17	A	<1%
KN	1	0	-	-	-	45	82,5	45	172,5	8	A	<1%
LV	1	0	-	-	-	83	77,5	39	170,5	12	B	1-5%
PF	1	0	-	-	-	50,5	110	15	175,5	13	VWS 1	
HM	1	0	-	-	-	no motion analysis				48	VWS 2A	
HJ	2	0	-	-	-	82	94,5	30	176,5	16	B	<1%
KB	2	0	-	-	-	181	110	30	241	18	A	<1%
RS	2	0	-	-	-	20	50	30	100	9	B	1-5%
MR	3	0	-	-	-	32,5	82,5	75	190	11	A	1-5%
NP	3	0	-	-	-	34	49,5	45	129,5	7	A	<1%
EA	1	1	-	-	-	110,5	105	60	275,5	25	A	1-5%
RR	1	1	-	-	-	110,5	115	30	255,5	28	A	<1%
RR	6	1	-	-	-	95	92	30	177	17	A	<1%
LR	2	3	-	-	-	77,5	82	30	189,5	28	A	<1%
MP	6	3	-	-	-	100,5	80	30	210,5	26	A	<1%
HL	6	8	-	-	-	no motion analysis				46	A	<1%
BJ	no US	-	-	-	-	23,5	62,5	30	116	8	A	<1%

HEAD-US Score (Haemophilia Early Arthropathy Detection with Ultrasound):

DISEASE ACTIVITY	SCALE
SYNOVITIS	
HYPERTROPIC SYNOVITIS	
0: Absent/Minimal	0
1: Mild/Moderate	1
2: Severe	2
DISEASE DAMAGE	
ARTICULAR SURFACES	
CARTILAGE	
0: Normal	0
1: Ectothecure abnormalities, focal partial/full-thickness loss of the articular cartilage involving <25% of the target surface*	1
2: Partial/full-thickness loss of the articular cartilage involving at least >50% of the target surface**	2
3: Partial/full-thickness loss of the articular cartilage involving >50% of the target surface*	3
4: Complete cartilage destruction or absent visualization of the articular cartilage on the target bony surface*	4
BONE	
0: Normal	0
1: Mild irregularities of the subchondral bone with/without initial osteophytes around the joint	1
2: Deformed subchondral bone with/without erosions and presence of prominent osteophytes around the joint	2

Notes:
* anterior aspect of the distal humeral epiphysis
* femoral trochlea
* ANKLE: anterior aspect of the talar dome

Except for central damage cartilage and bone defects of the joints are sonographically sufficiently well represented and quantified with the HEAD-US Score (by C. Martinoli) in patients with HA.

Because the results of the gait analysis are subjected especially in young patients disturbances such age-dependent coordination weakness a larger group of patients is needed to perform statistical analysis.

In our young patients from a German haemophilia treatment center (consistent treated with prophylaxis) compared to the results in the elderly patients (mostly treated with coagulation factors only on demand) significantly less damage to the articular cartilage and adjacent structures was shown.

Material and methods:

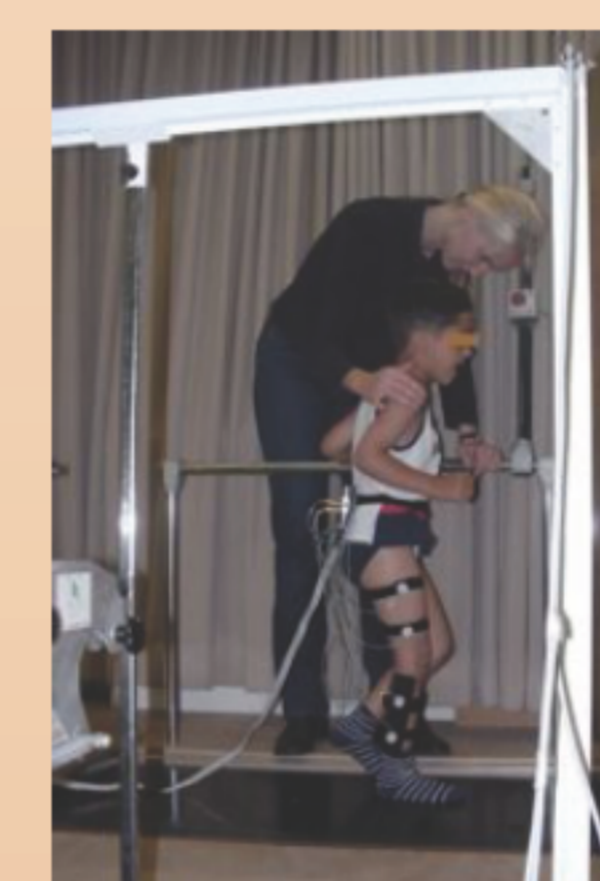
First experiences were made in a group of 27 young German patients (3-28 years, median 13.1) with hemophilia A, B or von Willebrand's disease (65% severe form of Haemophilia A, 11% Haemophilia B, 3% von Willebrand's disease type 3 and 7% von Willebrand's disease type 1 or 2).

A standardized ultrasonography of the elbow, knee and ankle joints with a Zonare „z.one ultra“ ultrasound machine (with linear transducer: L14-5w) and simultaneously a clinical examination and a 3D-motion-analysis with an Ultrasound-Topometer of the knees were performed.

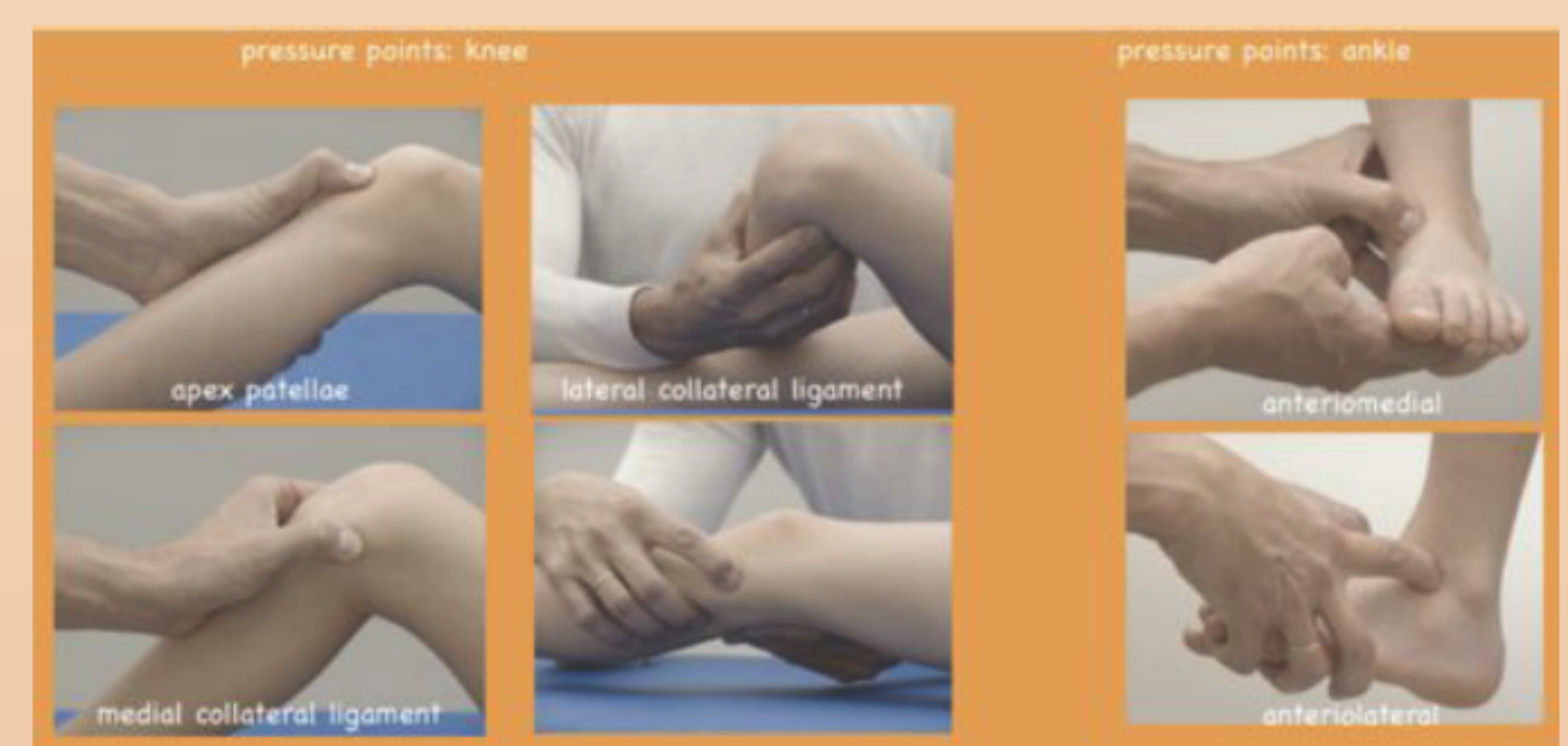
The Ultrasound-Topometer (developed at the University of Bonn, Germany) measures the time required for ultrasonic pulses from transmitters at defined points on the body of the patient (in motion) to four receivers, mounted in a rigid frame. The velocity of the ultrasonic wave and the length of the frame are known, therefore the exact location of limbs during the movement on a millimeter scale can be measured. A software program then calculates the angle, speed and acceleration. The calculated Motion-Score based on the magnitude of the deviation from the physiological, rhythmic movement, with higher values reflect a physiological movement with rolling instead of sliding movements.

Joint ultrasound characteristics were scored with the Score developed by C. Martinoli (HEAD-US). The scores and the results of the orthopedic examination were correlated.

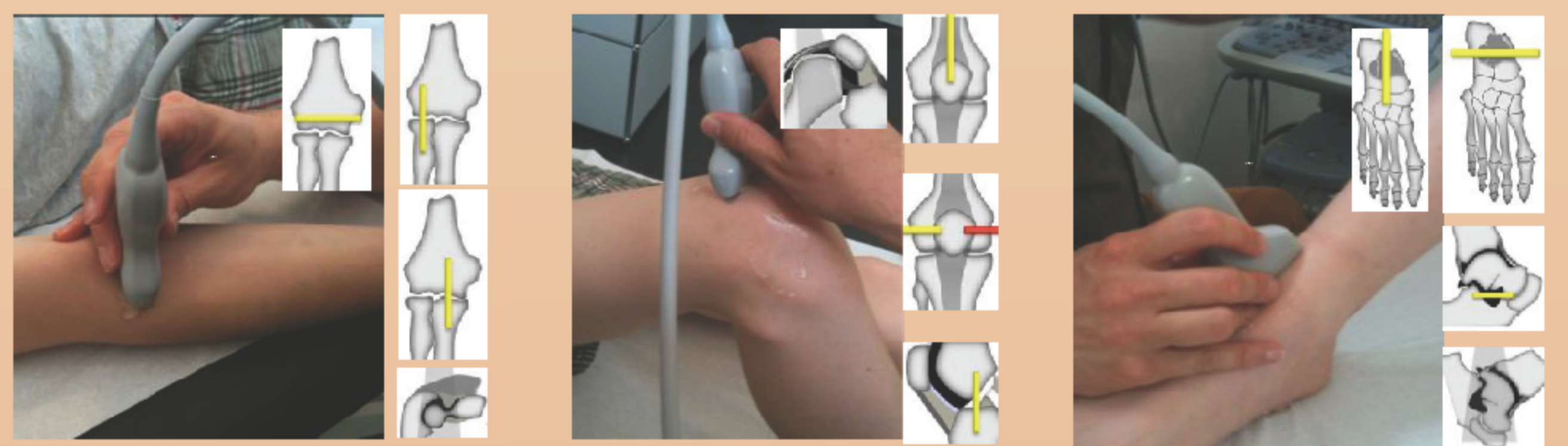
3D-motion-analysis:



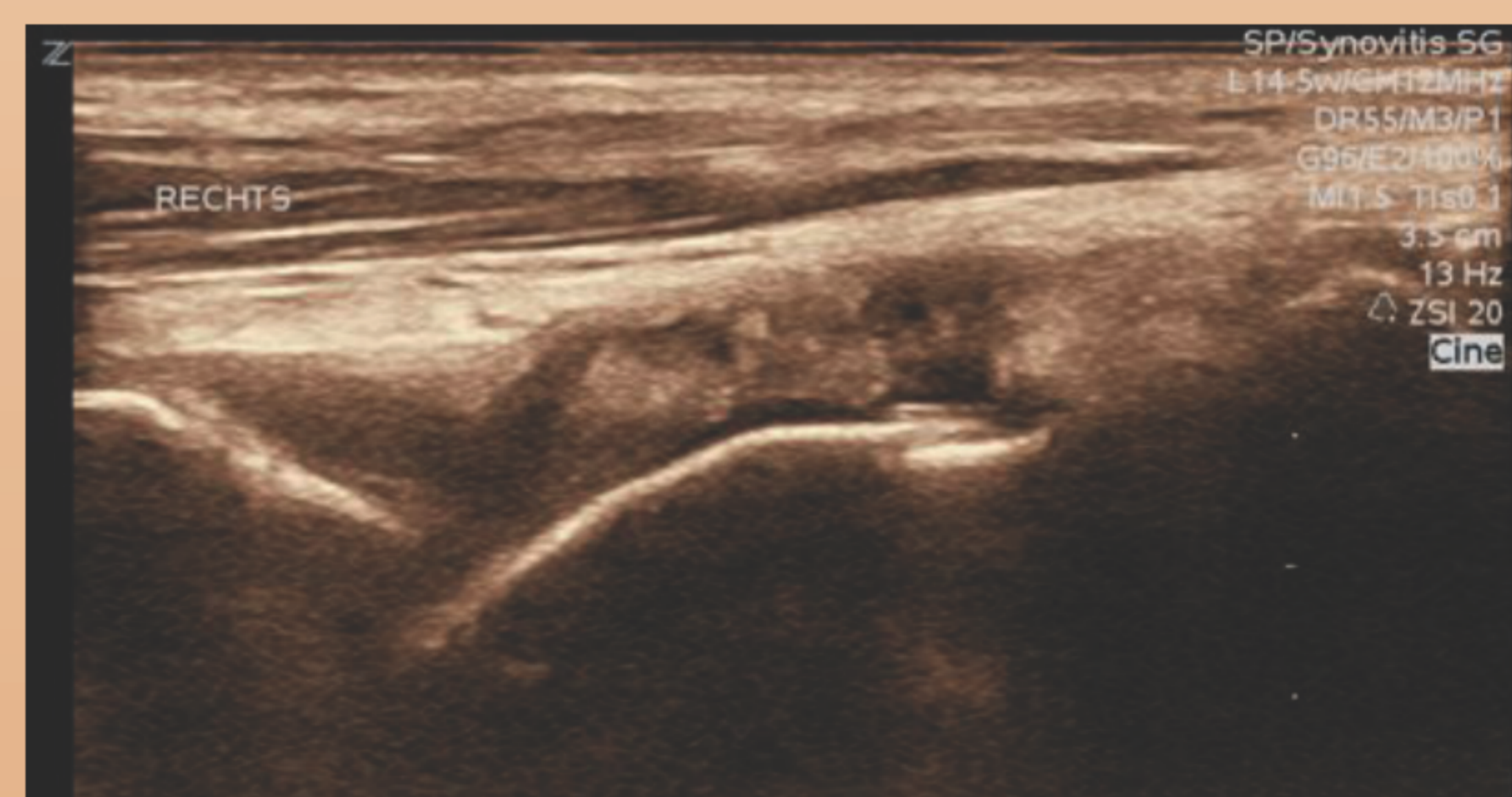
Pressure Points in Clinical orthopedic examination:



Sonographic examination - standard sections (elbow, knee, ankle joint):



Synovitis in Haemophilic Arthropathy (longitudinal section of the ankle):



Summary

Diagnostic ultrasound is clinically used for imaging of effusion, bleeding, synovialitis, cartilage or bone damage in joints of haemophilic patients. For the presentation of synovitis as a sign of activity and of defects of the articular cartilage and bone as a sign of progression of haemophilic arthropathy (HA), standardized section planes are now available (C. Martinoli).

Initial in 27 of our haemophilic patients, a standardized ultrasonography of the elbow, knee and ankle joints with a Zonare „z.one ultra“ ultrasound machine (linear transducer L14-5w) was performed. Simultaneously an orthopedic examination and a 3D motion analysis of the lower extremities were performed.

These initial studies in a cohort of haemophiliacs correlating a standardized sonographic diagnosis for detection of disease activity and joint function of a HA show age-dependent promising results. Joint sonography showed some changes already before that stood out in the clinical examination.

After these first promising results, a clinical Pilot-Trial was started in 2012 with up to now more than 140 examined German haemophiliacs to investigate the correlation between ultrasound, function and clinical findings in HA.

It may appear useful if haemophilia treaters in future learn and apply this method to control the therapy under close control and evaluation of joint changes. A good collection of joint changes is a good base for an optimal control of the therapy of haemophiliacs. The success of prophylactic factor substitution is with the ultrasound examination of the joints captured very well at any time.

References

Keshava S, Gibikote S, Mohanta A, Doria AS: Haemophilia 2009; 15: 1168-71
Martinoli C et al: J Thromb Haemost 2013; Jun 4;109(6):1170-9
Pergantou H et al.: Haemophilia 2006; 12 (3): 241-7
Seuser A, Schumpe G, Schumacher M, Lehmann K, Oldenburg J, Berdel P: Hämostaseologie 2009; 29 (Suppl 1): 569-573
Seuser A: Hämostaseologie 2012; 32: 52-61
Zukotynski K, Jarrin J, Babyn PS et al.: Haemophilia 2007; 13: 293-304

Sponsoring: This trial is supported as an investigator initiated trial by Pfizer Deutschland GmbH, Germany and Baxter Deutschland GmbH, Germany